



BERTOLOTTI'S SYNDROME: MANAGEMENT OF A TRANSITIONAL L5 SEGMENT WITH AN L4-L5 DISC EXTRUSION COMPRESSING THE L5 ROOT SLEEVE BUT CREATING CLASSIC S1 DERMATOME RADICULITIS

submitted by
Roy Siegel DC
New York, NY
October 29, 2010

also presented at NYCC Post Grad Cox® Course on December 4, 2010

Case History:

On June 25, 2010, a 43 year old male presented with complaints of pain in the right lower back, buttock, posterior thigh and leg. Paresthesia was present in the lateral portion of the sole of the right foot that had started one week prior. His VAS was 3 while in the supine position and 10 concentrated in the right buttock while sitting. Standing and walking produced moderate pain. He could lift heavy weights without extra pain. Pain reduced his ability to sleep by 50%. Pain reduced his ability to sit for more than 1/2 hour. One week earlier he had been given prednisone for inflammation relief. He mentioned that he had suffered with periodic back pain ever since he was 12 years old. Radiographs taken at that time revealed a scoliotic spine.

Health History:

The patient mentioned that he has been diagnosed with psoriatic arthritis in the past. He was not taking any medications.

Physical Examination:

The patient is 5' 11" tall and weighs 179 pounds. Observation revealed a significant left lumbar antalgia. An apparent right short leg was present in supine and prone position.

- SPINAL RANGES OF MOTION: Pain radiation into the right acetabular area resulted from cervical flexion (60 degrees). Lumbar flexion of 30 degrees created severe right buttock pain.
- ORTHOPEDIC EXAMINATION: Lasegues test created severe right buttock pain at 40 degrees. Achilles reflex was 1 on right, 2 on left. Braggards, Leg Drop Test and Fabre Patrick all were negative. Toe walking increased the right foot parasthesia. No motor deficit was present, including dorsiflexion and plantar flexion of the first toes.

Lumbar Spine Imaging:

MR of the lumbar spine was performed on June 30, 2010 and revealed at L3-L4 a small central disc extrusion extending rostrally behind the L3 vertebral body. This was superimposed upon mild disc annulus bulging. In combination with facet and ligament hypertrophy there was a mild central canal stenosis. See Figure 1.

At L4-L5 there was a large inferiorly extruded disc fragment on the right extending inferiorly into the lateral recess at the upper margin of the transitional L5 vertebral body. This was compressing the right L5 nerve root sleeve in the lateral recess. Hypertrophic degeneration facet arthropathy and ligamentum flavum hypertrophy contributed to mild to moderate central canal stenosis. There was bilateral foraminal stenosis as well. See Figures 2 and 3.

At L5-S1, there was no disc herniation, neural impingement or spinal stenosis. A transitional L5 vertebra is present at the lumbosacral junction and is considered a partially "sacralized" L5. This may be why the dermatome radiation seems to be the typical S1 nerve root pattern.

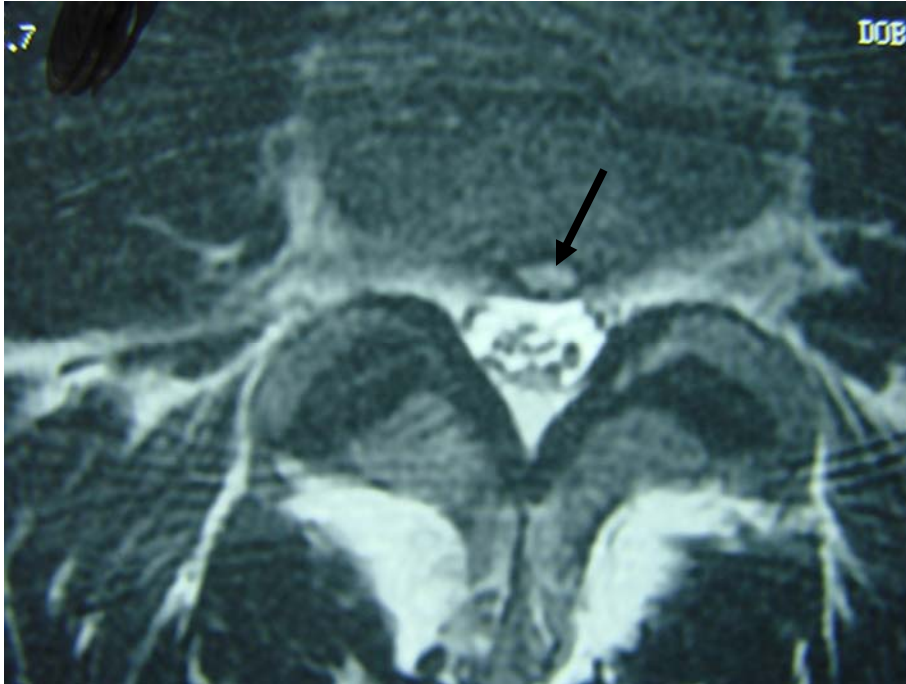


Figure 1. This is the axial image showing the L3-L4 small central disc extrusion. (see arrow)

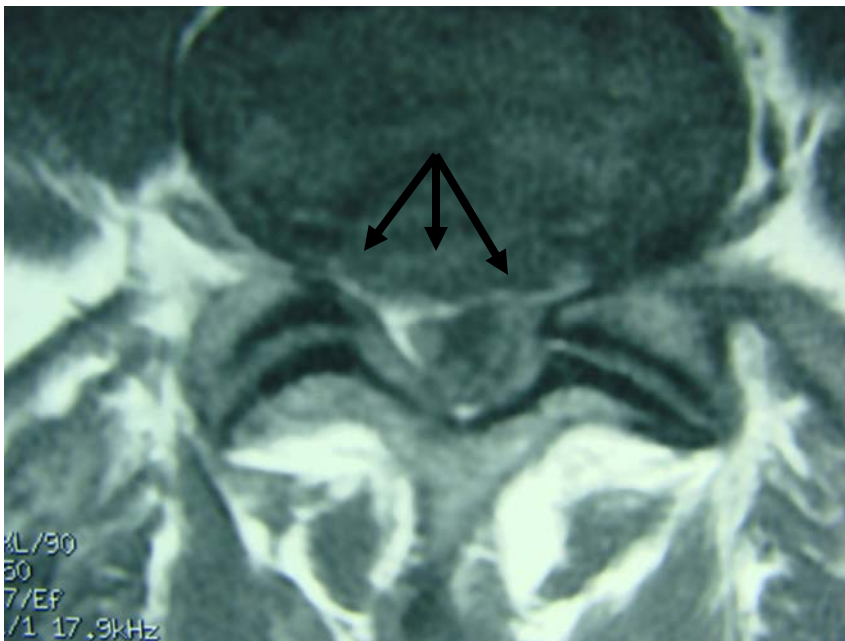

Figure 2. This is the axial image showing the extensive right sided and central large disc extrusion from the L4-L5 disc level (see arrow) that extends from central to the right lateral recess to stenose the vertebral and osseoligamentous canal. This axial image is posterior to the L4-L5 intervertebral disc space. This is capable of compressing the right L5 nerve root within the lateral recess as well as the cauda equina containing the sacral nerve roots within the cauda equina.

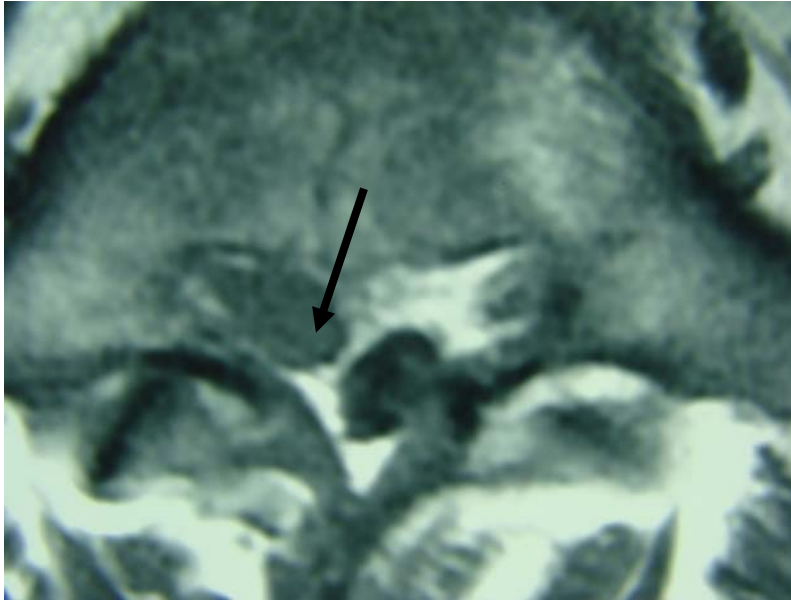


Figure 3. Note the free fragment of L4-L5 sequestered disc material lying within the central canal. (see arrow) that contacts the L5 nerve root. This axial view is taken behind the transitional L5 segment, representing the fragment of disc seen has migrated inferior behind the fifth lumbar vertebral body which is a transitional segment.

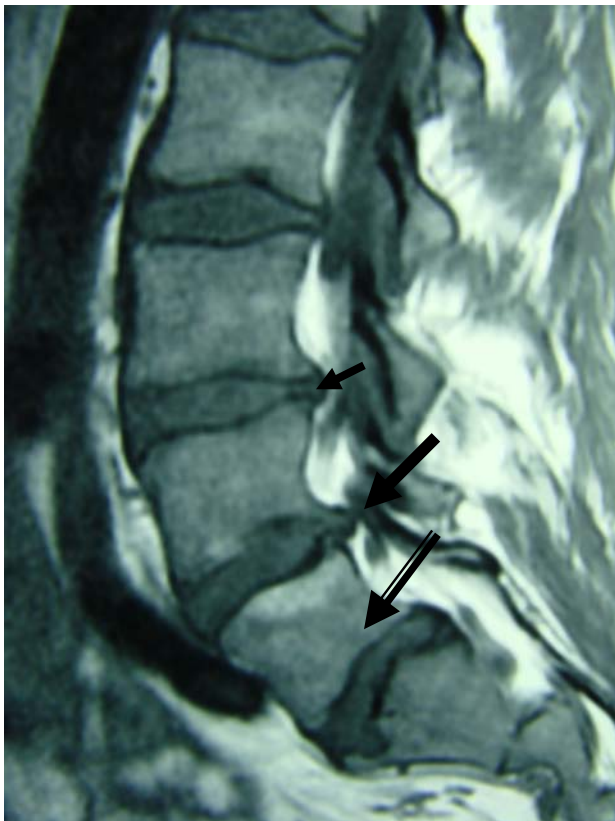

Figure 4. Here is the sagittal image showing the L3-L4 disc protrusion (small arrow) and the L4-L5 disc extrusions and free fragment. (large arrow) The transitional segment is at the double arrow.



Diagnosis: Large extrusion with disc sequestration of L4-L5 on the right side with resultant probable L5 and S1 nerve root compression and chemical inflammation. A small central L3-L4 disc protrusion is also present. The combined L4-L5 disc herniation and the transitional segment at the L5 level is termed Bertolotti's syndrome.

Treatment plan: Treatment consisted of Cox® flexion-distraction decompression adjustments of the L4-L5 intervertebral disc, adjustments of the pelvis at the right pubic bone, right superior femur and right calcaneus. Targeted goading of involved musculature (adductors, multifidi, gemelli, obturators, gluteus maximus, hamstrings) was performed. Frequency specific micro-current and infra-sound were applied to the L4-L5 disc area. Home care included minimizing sitting, smiling to increase risorius neuro-muscular feedback, posture improvement, epsom salt baths using maximum magnesium sulfate concentration, utilizing a racquet ball against a wall to self goad the paraspinal, gluteal and tensor fascia lata musculature .

Clinical Outcome:

After the 3rd visit lumbar flexion increased from 30 degrees to over 90 degrees and produced no pain. After the 6th visit less discomfort was noted while driving. Less paresthesias was noted when toe walking. Psoas muscles were less contracted.

After the 10th visit (approximately 2 months after treatment started) the patient reported "I'm good". Most numbness was gone, pain was better in the right buttock. Intermittent cramping was still present and the patient was reminded to take the epsom salt baths to maximize magnesium input and increase muscle relaxation. After the 11th visit (2 weeks later) the right Achille's reflex had returned to an optimal 2 level, equal to the left Achille's reflex.

Conclusion:

The patient is co-owner of swimming pool company and has found field work to be less irritating. Until he stops sitting as well as reducing other mechanical and mental stress, he has agreed that Cox® Technic applied every 2 weeks shall allow him to maintain his improved state of health.